



Thoracic vertebral count and thoracolumbar transition in *Australopithecus afarensis*

Carol V. Ward^{a,1}, Thierra K. Nalley^b, Fred Spoor^{c,d}, Paul Tafforeau^e, and Zeresenay Alemseged^f

^aIntegrative Anatomy Program, Department of Pathology and Anatomical Sciences, University of Missouri, Columbia, MO 65212; ^bDepartment of Medical Anatomical Sciences, College of Osteopathic Medicine of the Pacific, Western University of Health Sciences, Pomona, CA 91766-1854; ^cDepartment of Human Evolution, Max Planck Institute for Evolutionary Anthropology, Leipzig 04103, Germany; ^dDepartment of Cell and Developmental Biology, University College London, London WC1E 6BT, United Kingdom; ^eEuropean Synchrotron Radiation Facility, CS-40220 38043 Grenoble Cedex 09, France; and ^fDepartment of Organismal Biology and Anatomy, University of Chicago, Chicago, IL 60637

Edited by Bruce Latimer, Case Western Reserve University, Cleveland, OH, and accepted by Editorial Board Member C. O. Lovejoy March 26, 2017 (received for review February 8, 2017)

The evolution of the human pattern of axial segmentation has been the focus of considerable discussion in paleoanthropology. Although several complete lumbar vertebral columns are known for early hominins, to date, no complete cervical or thoracic series has been recovered. Several partial skeletons have revealed that the thoracolumbar transition in early hominins differed from that of most extant apes and humans. *Australopithecus africanus*, *Australopithecus sediba*, and *Homo erectus* all had zygapophyseal facets that shift from thoracic-like to lumbar-like at the penultimate rib-bearing level, rather than the ultimate rib-bearing level, as in most humans and extant African apes. What has not been clear is whether *Australopithecus* had 12 thoracic vertebrae as in most humans, or 13 as in most African apes, and where the position of the thoracolumbar transitional element was. The discovery, preparation, and synchrotron scanning of the *Australopithecus afarensis* partial skeleton DIK-1-1, from Dikika, Ethiopia, provides the only known complete hominin cervical and thoracic vertebral column before 60,000 years ago. DIK-1-1 is the only known *Australopithecus* skeleton to preserve all seven cervical vertebrae and provides evidence for 12 thoracic vertebrae with a transition in facet morphology at the 11th thoracic level. The location of this transition, one segment cranial to the ultimate rib-bearing vertebra, also occurs in all other early hominins and is higher than in most humans or extant apes. At 3.3 million years ago, the DIK-1-1 skeleton is the earliest example of this distinctive and unusual pattern of axial segmentation.

Australopithecus afarensis | vertebrae | Dikika | segmentation | thoracic

A partial skeleton attributed to *Australopithecus afarensis* from Dikika, Ethiopia, dated to 3.3 Ma (1), provides the only known complete cervical and thoracic vertebral column of any early hominin prior to 60,000 years ago (2).

The modal number of thoracic and lumbar vertebrae has been a key factor in interpretations of the evolution of locomotor adaptations in hominoids (3–15). A larger number of thoracic and smaller number of lumbar vertebrae increase dorsostability of the trunk (8, 16–19) and are found in various combinations in extant apes (10, 11, 13, 15, 17, 19). Like humans, early hominins had five non-rib-bearing lumbar vertebrae, as demonstrated in three species: *Australopithecus africanus*, *Australopithecus sediba*, and *Homo erectus* (3, 4, 6, 7, 10, 14, 20). However, a lack of a complete thoracic column for any early hominin has made it difficult to determine whether early hominins had only 12 thoracic vertebrae like humans, or 13, as in extant African apes, or whether variation in segmentation patterns involved addition or deletion of segments or a shift in identity among segments (10, 11, 13, 15).

In addition to uncertainty in thoracic count, there is also variation in the configuration of the thoracolumbar transition, in which early hominins differ from most extant hominids (4, 7, 10, 20). In most extant hominids, the caudal-most rib-bearing vertebra usually has flat cranial zygapophyseal facets facing dorsally or very slightly dorsolaterally, as is typical of thoracic vertebrae. In contrast, the caudal zygapophyseal facets of this vertebra are transversely convex

and are generally oriented posteromedially, averaging about 30° to 45° to a sagittal plane, like those of upper lumbar vertebrae (21–23). This vertebra, which exhibits the transition from thoracic-like to lumbar-like zygapophyses, is referred to as the transitional or diaphragmatic vertebra. The transition in facet orientation from thoracic to lumbar patterns occurs gradually over two to three segments in 43 to 93% of human individuals (depending on how facet morphology is quantified), but the transition is usually complete no higher than the last rib-bearing thoracic vertebra (21–30). When an abrupt transition occurs within only a single vertebra, it typically occurs at the last rib-bearing element but can be found one segment higher (11th thoracic, or T11) in up to ~10 to 23% of individuals (10, 23, 28, 29). Thus, when a transition is abrupt, most modern humans and extant great apes have a transitional vertebra at the last rib-bearing vertebra. Due to differences in the numbers of non-rib-bearing lumbar vertebrae among apes and humans, this transition usually occurs at the sixth presacral level (T12) in modern humans versus the fourth or fifth presacral levels (T13) in extant great apes (8–10).

All four early hominin fossils that preserve the transitional region exhibit a different pattern, compared with the most frequent pattern seen in extant hominoids (4, 7, 10). The *A. africanus* skeleton Sts 14 has an abrupt transitional element situated at the seventh—not sixth—presacral level (Sts 14g), even though the sixth presacral element has a distinct rib on the right side (4, 6). The *A. africanus* skeleton StW 431 also has an abrupt transitional element at the seventh presacral level and probably had only five

Significance

The discovery of a 3.3 million-year-old partial skeleton of *Australopithecus afarensis*, from Dikika, Ethiopia, preserved all seven cervical (neck) vertebrae and provided the only known evidence for the presence of 12 thoracic (rib-bearing) vertebrae in hominins prior to 60,000 years ago. This skeleton has seven cervical and only 12 thoracic vertebrae like humans, rather than 13 like African apes. However, the anatomical transition from thoracic to lumbar (lower back) vertebral form occurs at the 11th thoracic segment. This distinctive pattern of vertebral segmentation, rare in modern apes and humans, is also seen in the three other early hominins for which this area is known, with the Dikika skeleton providing the earliest and most complete example.

Author contributions: C.V.W. and Z.A. designed research; C.V.W., T.K.N., F.S., P.T., and Z.A. performed research; C.V.W., T.K.N., F.S., and Z.A. analyzed data; and C.V.W., T.K.N., F.S., P.T., and Z.A. wrote the paper.

The authors declare no conflict of interest.

This article is a PNAS Direct Submission. B.L. is a guest editor invited by the Editorial Board.

Data deposition: The DIK-1-1 fossil is housed at the National Museum of Ethiopia. Requests to study it should be made to the museum and to Z.A. (alemseged@uchicago.edu). Scan data are archived at the University of Chicago and the European Synchrotron Radiation Facility (requests for these data should also be made to Z.A.).

¹To whom correspondence should be addressed. Email: WardCV@missouri.edu.

non-rib-bearing lumbar vertebrae, based on a tiny raised area adjacent to where a costal facet would be on the sixth presacral vertebra (4, 5). The *A. sediba* specimen MH2 preserves the

penultimate and ultimate rib-bearing vertebrae, with the penultimate vertebra being an abrupt transitional element, as in the *A. africanus* skeletons (7). Similar to what is seen in these

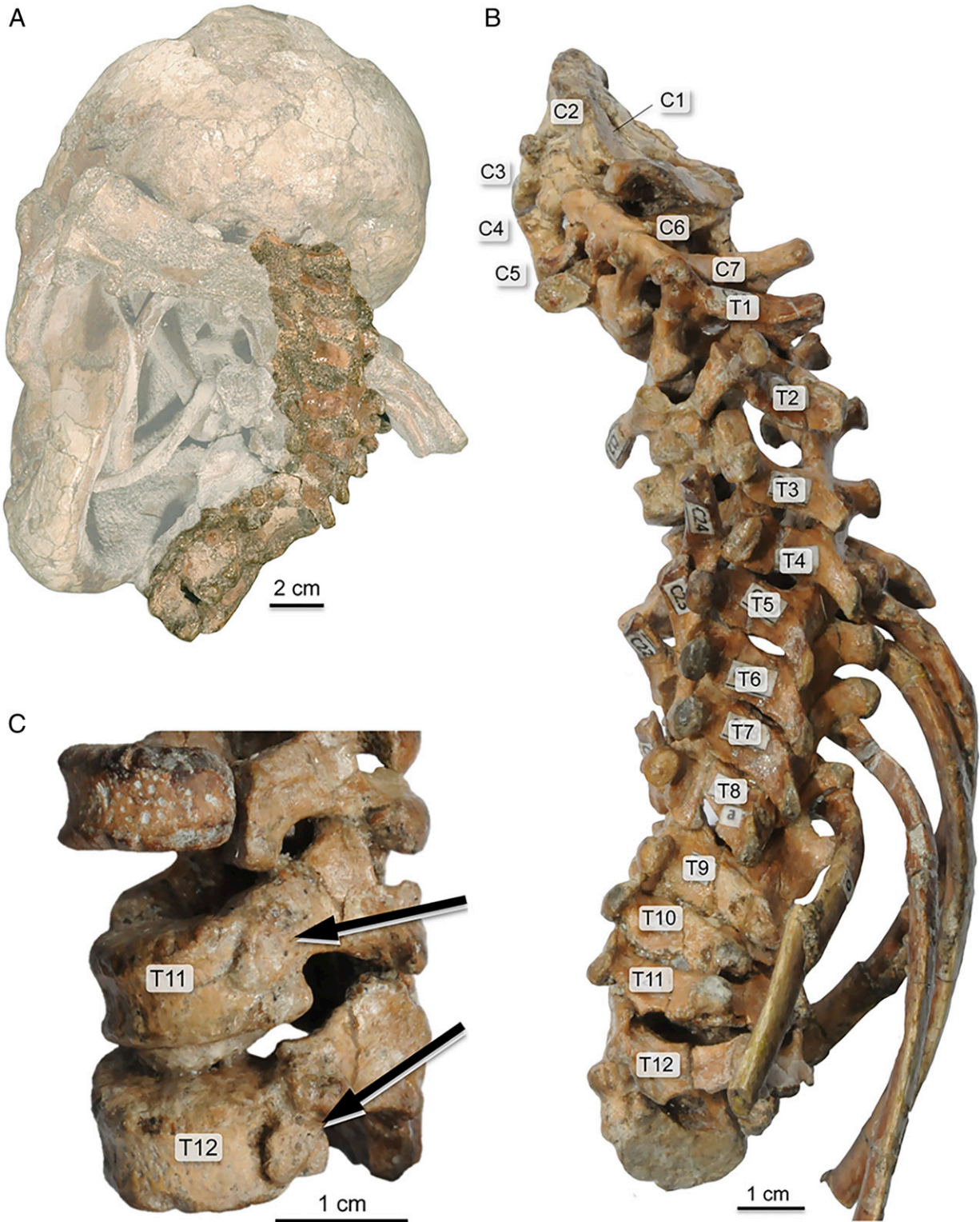


Fig. 1. (A) Photograph of the DIK-1-1 vertebrae in block with skull, pectoral girdle, and rib fragments before complete preparation. The vertebral column is highlighted. (B) Entire articulated cervical and thoracic column of DIK-1-1, with vertebral levels indicated on each bone, demonstrating the presence of seven cervical and 12 thoracic (rib-bearing) vertebrae. Most of these vertebrae cannot be disarticulated mechanically. (C) The three caudal-most preserved vertebrae—T10, T11, and T12—with rib facets indicated (arrows) on T11 and T12.

earlier *Australopithecus* specimens, the 1.6-million-year-old *H. erectus* skeleton KNM-WT 15000 also possesses five non-rib-bearing lumbar elements and a transitional vertebra situated at the seventh presacral level (3). The likely presence of the transition occurring at the penultimate rib-bearing level has been suggested for the *A. afarensis* specimen A.L. 288-1 as well (20). In all of these specimens, therefore, the transitional element is at the second-to-last rib-bearing vertebra, not the last rib-bearing one, contrasting with the most frequent condition seen in extant hominoids.

Because an abrupt transitional element at the penultimate rib-bearing vertebra is found in only 1 to 23% of modern humans (10, 23, 27), the probability of finding all five of these specimens (Sts 14, StW 431, MH 2, KNM-WT 15000, and DIK-1-1) in a modern human population with a similar frequency is less than 0.0007%, and, if the same indeed characterizes A.L. 288-1, the probability drops to less than 0.0001%.

Although the early hominin transitional element has been referred to as the 11th thoracic vertebra (T11) in the literature (4, 10, 20, 31), this claim was speculative because, at the time, no complete thoracic vertebral column had been recovered for any *Australopithecus* specimen. With the discovery of the juvenile *A. afarensis* skeleton, DIK-1-1 at Dikika, Ethiopia (1) (Fig. 1), the required evidence has now become available.

Results

The original description of DIK-1-1 reported the presence of two lumbar vertebrae (1), but subsequent cleaning and preparation, as

well as evidence from microtomographic images, revealed that these were thoracic elements and that no lumbar or sacral elements had been preserved. Some of the unfused vertebral bodies were not in anatomical position when discovered but have now been rear-articulated with their corresponding neural arches. Each thoracic vertebra preserves visible articular facets for ribs, and portions of all costal elements are represented. Importantly, all of the neural arches are preserved in sequence and in articulation, making identification of the various vertebrae and our interpretation of their morphology and relationship straightforward.

The morphology of the 11th and 12th thoracic vertebrae (T11 and T12) of DIK-1-1 is particularly informative. Both preserve single costal facets on both the right and left side, typical of the caudal-most two thoracic elements in all extant hominoids (Fig. 1). The zygapophyseal facets are well preserved. The T11 of DIK-1-1 has flat cranial zygapophyseal facets that lie in a coronal plane (~90° to a sagittal plane) cranially but has transversely convex and lumbar-like caudal facets that face 30° ventrolaterally relative to a sagittal plane (Fig. 2). This configuration clearly identifies T11 as the transitional element and documents an abrupt transition in this individual.

Both cranial and caudal facets on T12 are lumbar-like (cranial facets oriented 30° and caudal facets oriented 25° to a sagittal plane). Thus, the transition pattern of zygapophyseal facet morphology found in the T11 and T12 of DIK-1-1 resembles the transition pattern observed in four other early hominins, but not that of a majority of modern humans.

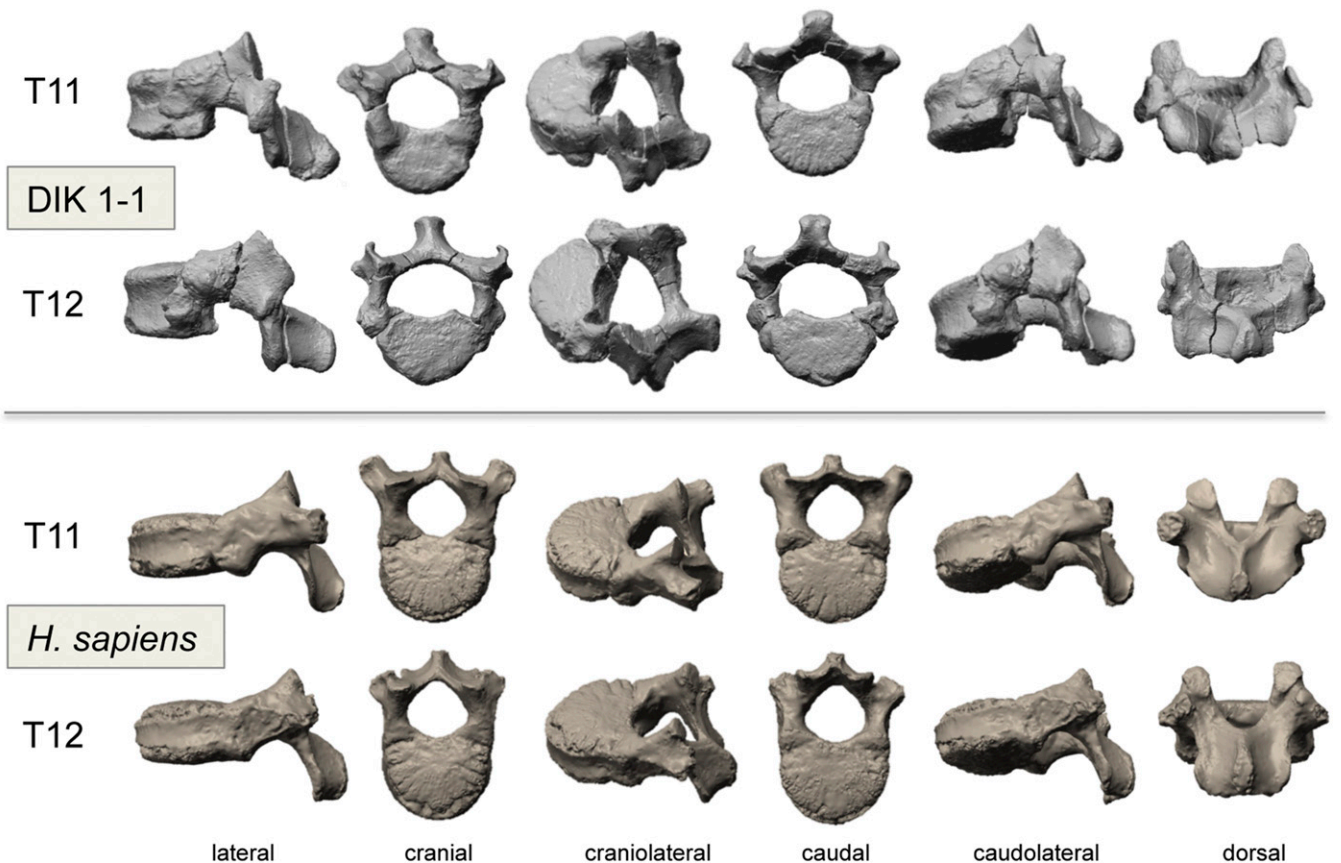


Fig. 2. In silico digital reconstructions of the 11th and 12th thoracic vertebrae of DIK-1-1 and a modern *H. sapiens* juvenile (age estimated at roughly 6 to 8 years of age), kindly provided by Libby Cowgill, Department of Anthropology, University of Missouri, Columbia, MO. DIK-1-1 reconstruction is based on synchrotron data; the *H. sapiens* specimen is from surface scans taken with a NextEngine desktop laser scanner. The DIK-1-1 T11 has flat, paracoronally oriented cranial zygapophyseal facets, but obliquely oriented and transversely convex caudal zygapophyseal facets, and thus is the transitional vertebra. On the DIK-1-1 T12, both cranial and caudal zygapophyseal facets are obliquely oriented and transversely convex, which contrasts with the typical human condition, shown here, in which T11 has flat, paracoronally oriented zygapophyseal facets cranially and caudally, but shows the transitional morphology on T12.

Discussion

The DIK-1-1 skeleton demonstrates that the distinctive vertebral segmentation pattern seen in four other early hominins, with an abrupt facet transition at the penultimate rib-bearing vertebra, was present at least by 3.3 million years ago in *A. afarensis*. This specimen also preserves 12 thoracic vertebrae. Because the presence of a transitional vertebra cranial to the penultimate or second-to-last rib-bearing element is very rare among extant hominoids (*H. sapiens* <0.1%; *Pan troglodytes* 0.4%; *Gorilla gorilla* 1.5%; *Gorilla beringei* 1.5%; *Symphalagus syndactylus* 2.8%; unobserved in *Pan paniscus*, *Pongo pygmaeus* and *Hylobates lar*) (8–10), it is highly improbable that other *A. afarensis* would have had 13 thoracic vertebrae. We therefore can conclude confidently that *A. afarensis* had 12 thoracic vertebrae, as is modal for humans and unlike the pattern in all but a few African apes (10, 11, 13, 15, 16, 18).

The A.L. 288-1 partial skeleton (*A. afarensis* from Ethiopia) (31) preserves some lumbar and thoracic vertebrae. Specimen A.L. 288-1ai has been referred to as a last thoracic vertebra, based on the transitional morphology of its cranial and caudal facets, with the latter being elongated, convex, and facing anterolaterally, and called T12 under the assumption that *A. afarensis* had 12 thoracic elements and that the transition was at T12 (20). However, based on the transition pattern typical for all other early hominins, including DIK-1-1, A.L. 288-1ai is likely a penultimate thoracic (see also ref. 31). If so, the more cranially positioned thoracic vertebrae may also represent higher levels than originally reported.

Comparison between the DIK-1-1 T11 and A.L. 288-1ai shows that the curvature and oblique orientation of the caudal zygapophyseal facets are even more prominent in A.L. 288-1, probably reflecting ontogenetic differences in morphology. Developmental changes in lumbar zygapophyseal facet orientation and curvature have been reported for humans (32, 33). Lumbar zygapophyseal joints lie in the coronal plane at birth, similar to those of thoracic vertebrae, and subsequently rotate inward a sagittal plane and become more curved during growth, reaching adult morphology by late adolescence or early adulthood (34), which suggests that the rotation into the sagittal plane and curvature of the T11 caudal facets of DIK-1-1 and both sets of T12 facets would likely have increased during development.

Because DIK-1-1 has no preserved lumbar vertebrae, its lumbar count cannot be assessed. However, it is reasonable to hypothesize that DIK-1-1 would have had five lumbar segments, as do all sufficiently preserved ($n = 3$) early hominins. DIK-1-1 is unlikely to have had more than five non-rib-bearing lumbar vertebrae because it has the transitional element at the second-to-last rib-bearing segment. No extant African ape has a transitional element cranial to the seventh presacral vertebra, and this morphology is extremely rare in humans (<0.1%, $n = 1,159$) (10). It is unlikely, though less certain, that DIK-1-1 had fewer than five non-rib-bearing lumbar segments. Given that a count of only 16 thoracolumbar vertebrae is rare in modern humans (4.9%, $n = 1,159$) (10) and unknown in other early fossil hominins, this scenario is much less likely. Seventeen thoracolumbar vertebrae also is the most common pattern in most African apes although a count of 16 or fewer is slightly more common in apes than in humans [*P. paniscus* 6.3% ($n = 48$), *P. troglodytes* 24.3% ($n = 239$), *Gorilla gorilla gorilla* 29.6% ($n = 86$), although *Gorilla beringei beringei* is 95.5% ($n = 66$)] (10). It is therefore possible to infer that early hominins modally had 12 thoracic and five non-rib-bearing lumbar vertebrae as their modal vertebral counts, with a transitional element at T11. This evidence supports the early hominin modal vertebral formula proposed by Pilbeam (11) and Williams et al. (10). The shifting morphology and identity of the thoracolumbar transitional vertebrae seems to have been a change involving a shift in segment identity, or identity of parts of the segment (i.e., costal articulations versus zygapophyseal morphology), rather than a meristic shift involving addition or deletion of elements (11, 13).

The location of the thoracolumbar transitional element may affect function of the vertebral column. Medially oriented lumbar-like zygapophyseal facets restrict rotation of the vertebral motion segments because the center of rotation is located within the intervertebral disk (29, 34). Having a more cranial transition to this type of facet would in principle result in more limited rotation of the lumbar spine in early hominins, perhaps by 2° to 3°. In DIK-1-1, the mammillary processes of T12 extend dorsally to flank the T11–T12 zygapophyseal joint, forming a “mortice”-style joint like that found in up to 47% of modern humans (25). Such a configuration would have further limited rotational capacity (35–38), at least in this individual (28). However, the range for spinal flexion and extension may have been equivalent to that of modern humans (34, 39), even given the deep lumbar capture between the iliac blades found in *Australopithecus* (40). A higher thoracolumbar transition may have permitted the ability to achieve a lumbar lordosis in *A. afarensis*—a key component of habitual upright bipedal locomotion in hominins (40, 41). Shifting the transition back to the ultimate rib-bearing element in later *Homo*, perhaps also indicating a freed lower lumbar region with reduced lumbar capture within the pelvis, may have increased the capacity for lumbar spinal rotation between the torso and pelvis (8, 13, 40–44) during modern human walking and running. This movement, in conjunction with other joint rotations (e.g., shoulders and knees), acts to balance and cancel angular moments around the spinal column during bipedal locomotion (45–48). The caudal shift in the thoracolumbar transition may be a component of a suite of derived features that have been argued to represent an adaptation for more efficient long-distance walking and endurance running in later *Homo*, and, if so, this particular component would have occurred only after 1.6 Ma with KNM-WT 15000 (48, 49).

Regardless of the functional significance of the modern human pattern, the DIK-1-1 skeleton provides evidence that *A. afarensis* had 12 thoracic vertebrae, with a thoracolumbar transitional element at T11, and that the thoracolumbar transitional morphology, present in four other known early hominins, evolved by at least 3.3 million years ago. This distinctive early hominin vertebral configuration may be a key to building and testing scenarios for the evolution of bipedality and body form in early hominins.

Materials and Methods

The upper part of the DIK-1-1 skeleton, which includes the skull and most of the torso, was found largely articulated and encased in a highly compact sandstone block, making preparation difficult and time-consuming. Significant mechanical preparation has been done at the National Museum of Ethiopia by Z.A. and Christopher Kiarie for over 13 years since its discovery and continues. Many of the elements, particularly the vertebrae, are now exposed (Fig. 1). In addition, the fossil was scanned using propagation phase contrast synchrotron microtomography on beamline ID17 at the European Synchrotron Radiation Facility (ESRF) in Grenoble, France, using a 100-keV monochromatic beam, with a voxel size of 45 μm and 5 m of propagation, providing us with the opportunity to virtually examine the vertebrae. These tomographic images were segmented by T.K.N. to isolate individual vertebral elements and their morphology. The DIK-1-1 fossil is housed at the National Museum of Ethiopia. Requests to study it should be made to the museum and to Z.A. (alernseg@uchicago.edu). Scan data are archived at the University of Chicago and the European Synchrotron Radiation Facility (requests for these data should also be made to Z.A.).

ACKNOWLEDGMENTS. We thank Christopher Kiarie and the staff at the Authority for Research and Conservation of Cultural Heritage, Ethiopia, for help during the preparation of these fragile fossils. We thank the curators and staff of the Ditsong Museum of Natural History, the University of the Witwatersrand, the American Museum of Natural History, the Cleveland Museum of Natural History, and the Powell Cotton Museum for access to comparative specimens. We thank Casey Holliday for help with data segmentation and figures and Libby Cowgill for specimens. This research and T.K.N.'s postdoctoral fellowship were supported generously by Margaret and Will Hearst. Additional support came from National Science Foundation Grant BCS 0716244 (to C.V.W.) and European Synchrotron Radiation Facility Grant EC-597 (to F.S. and Z.A.).

1. Alemseged Z, et al. (2006) A juvenile early hominin skeleton from Dikika, Ethiopia. *Nature* 443:296–301.
2. Bar-Yosef Y, et al. (1996) The dating of the Upper Paleolithic layers in Kebara Cave, Mt. Carmel. *J Archaeol Sci* 23:297–306.
3. Haeusler M, Schiess R, Boeni T (2011) New vertebral and rib material point to modern bauplan of the Nariokotome *Homo erectus* skeleton. *J Hum Evol* 61:575–582.
4. Haeusler M, Martelli SA, Boeni T (2002) Vertebrae numbers of the early hominid lumbar spine. *J Hum Evol* 43:621–643.
5. Toussaint M, Macho G, Tobias P, Partridge T, Hughes A (2003) The third partial skeleton of a late Pliocene hominin (Stw 431) from Sterkfontein, South Africa. *S Afr J Sci* 99:215–223.
6. Robinson JT (1972) *Early Hominid Posture and Locomotion* (Univ of Chicago Press, Chicago).
7. Williams SA, et al. (2013) The vertebral column of *Australopithecus sediba*. *Science* 340:1232296–1–1232296–5.
8. Erikson GE (1963) Brachiation in New World monkeys and in anthropoid apes. *Symp Zool Soc Lond* 10:135–164.
9. Williams SA (2012) Placement of the diaphragmatic vertebra in catarrhines: Implications for the evolution of dorsostability in hominoids and bipedalism in hominins. *Am J Phys Anthropol* 148:111–122.
10. Williams SA, Middleton ER, Villamil CI, Shattuck MR (2016) Vertebral numbers and human evolution. *Am J Phys Anthropol* 159:S19–S36.
11. Pilbeam D (2004) The anthropoid postcranial axial skeleton: Comments on development, variation, and evolution. *J Exp Zool B Mol Dev Evol* 302:241–267.
12. Williams SA (2012) Modern or distinct axial bauplan in early hominins? Comments on Haeusler et al. (2011). *J Hum Evol* 63:552–556, discussion 557–559.
13. Williams SA (2012) Variation in anthropoid vertebral formulae: Implications for homology and homoplasy in hominoid evolution. *J Exp Zool B Mol Dev Evol* 318:134–147.
14. Latimer B, Ward CV (1993) The thoracic and lumbar vertebrae. *The Nariokotome Homo erectus Skeleton*, eds Walker A, Leakey RE (Harvard Univ Press, Cambridge, MA), pp 266–293.
15. McCollum MA, Rosenman BA, Suwa G, Meindl RS, Lovejoy CO (2010) The vertebral formula of the last common ancestor of African apes and humans. *J Exp Zool B Mol Dev Evol* 314:123–134.
16. Schultz AH (1930) The skeleton of the trunk and limbs of higher primates. *Hum Biol* 2:303–438.
17. Schultz AH (1938) The relative length of the regions of the spinal column in Old World primates. *Am J Phys Anthropol* 24:1–22.
18. Schultz AH (1961) Vertebral column and thorax. *Primatologia* 4:1–66.
19. Schultz AH, Straus WL, Jr (1945) The numbers of vertebrae in primates. *Proc Am Philos Soc* 89:601–626.
20. Meyer MR, Williams SA, Smith MP, Sawyer GJ (2015) Lucy's back: Reassessment of fossils associated with the A.L. 288-1 vertebral column. *J Hum Evol* 85:174–180.
21. Masharawi Y, et al. (2004) Facet orientation in the thoracolumbar spine: Three-dimensional anatomic and biomechanical analysis. *Spine* 29:1755–1763.
22. Panjabi MM, et al. (1993) Articular facets of the human spine: Quantitative three-dimensional anatomy. *Spine* 18:1298–1310.
23. Singer KP, Breidahl PD, Day RE (1988) Variations in zygapophyseal joint orientation and level of transition at the thoracolumbar junction: Preliminary survey using computed tomography. *Surg Radiol Anat* 10:291–295.
24. Allbrook DB (1955) The East African vertebral column: A study in racial variability. *Am J Phys Anthropol* 13:489–513.
25. Davis PR (1955) The thoraco-lumbar mortice joint. *J Anat* 89:370–377.
26. Lanier R (1939) The presacral vertebrae of American white and negro males. *Am J Phys Anthropol* 25:341–420.
27. Pal GP, Routal RV (1999) Mechanism of change in the orientation of the articular process of the zygapophyseal joint at the thoracolumbar junction. *J Anat* 195:199–209.
28. Singer KP, Willen J, Breidahl PD, Day RE (1989) Radiologic study of the influence of zygapophyseal joint orientation on spinal injuries at the thoracolumbar junction. *Surg Radiol Anat* 11:233–239.
29. Shinohara H (1997) Changes in the surface of the superior articular joint from the lower thoracic to the upper lumbar vertebrae. *J Anat* 190:461–465.
30. White AA, Panjabi MM (1990) *Clinical Biomechanics of the Spine* (J. B. Lippincott, Philadelphia), 2nd Ed.
31. Johanson DC, et al. (1982) Morphology of the Pliocene partial hominid skeleton (A. L. 288-1) from the Hadar formation, Ethiopia. *Am J Phys Anthropol* 57:403–452.
32. Reichmann S (1971) The postnatal development of form and orientation of the lumbar intervertebral joint surfaces. *Z Anat Entwicklungsgesch* 133:102–123.
33. Taylor JR, Twomey LT (1986) Age changes in lumbar zygapophyseal joints. Observations on structure and function. *Spine* 11:739–745.
34. Kapandji IA (1974) *The Trunk and Vertebral Column, The Physiology of the Joints* (Churchill Livingstone, Edinburgh), Vol 3.
35. Slijper EJ (1946) *Comparative Biologic-Anatomical Investigations on the Vertebral Column and Spinal Musculature of Mammals*, Verhandelingen der Koninklijke Nederlandsche Akademie van Wetenschappen (North-Holland, Amsterdam), Vol 2, Part 42, Number 5.
36. Townsend HGG, Leach DH (1984) Relationship between intervertebral joint morphology and mobility in the equine thoracolumbar spine. *Equine Vet J* 16:461–465.
37. Haussler KK, Bertram JEA, Gellman K, Hermanson JW (2001) Segmental *in vivo* vertebral kinematics at the walk, trot and canter: A preliminary study. *Equine Vet J Suppl* 33:160–164.
38. Jones KE (2016) Preliminary data on the effect of osseous anatomy on ex vivo joint mobility in the equine thoracolumbar region. *Equine Vet J* 48:502–508.
39. Bodguk N, Twomey LT (1987) *Clinical Anatomy of the Lumbar Spine* (Churchill Livingstone, New York).
40. Rockwell H, Gaynor Evans F, Pheasant H (1938) The comparative morphology of the vertebrate spinal column: Its form as related to function. *J Morphol* 63:87–117.
41. Lovejoy CO (2005) The natural history of human gait and posture. Part 1. Spine and pelvis. *Gait Posture* 21:95–112.
42. Whitcome KK (2012) Functional implications of variation in lumbar vertebral count among hominins. *J Hum Evol* 62:486–497.
43. Russo GA (2010) Prezygapophyseal articular facet shape in the catarrhine thoracolumbar vertebral column. *Am J Phys Anthropol* 142:600–612.
44. Inman VT, Ralston HJ, Todd F (1981) *Human Walking* (Williams and Wilkins, Baltimore).
45. Hinrichs RN (1990) Upper extremity function in distance running. *Biomechanics of Distance Running*, ed Cavanagh PR (Human Kinetics Books, Champaign, IL), pp 107–133.
46. Herr H, Popovic M (2008) Angular momentum in human walking. *J Exp Biol* 211:467–481.
47. Pontzer H, Holloway JH, 4th, Raichlen DA, Lieberman DE (2009) Control and function of arm swing in human walking and running. *J Exp Biol* 212:523–534.
48. Bramble DM, Lieberman DE (2004) Endurance running and the evolution of *Homo*. *Nature* 432:345–352.
49. Lieberman DE, Bramble DM, Raichlen DA, Shea JJ (2009) Brains, brawn and the evolution of human endurance running capabilities. *The First Humans: Origin and Early Evolution of the Genus Homo*, eds Grine FE, Fleagle JG, Leakey RE (Springer, New York), pp 77–98.